

THE CORONATION OF THORNS IN THE LIGHT OF THE SHROUD

SEBASTIANO RODANTE

To celebrate its Tenth Anniversary, *Shroud Spectrum International* presents again a timeless study that appeared in the Pilot Issue of December 1981. It has long been maintained that the twofold "authenticity" of the Shroud—that is, the Cloth is truly a shroud, the Image is truly Jesus Christ—is manifest in its intrinsic characteristics. Of these characteristics, the simplest, most conspicuous, most telling, appears on the forehead of the Man of the Shroud in two blood-flows, seemingly very similar one to the other. But the difference in origin, medically discovered only in our century, provides astounding information.

As Dr. Rodante remarks, the evidence is there for all to see. From a thorn puncture in the right temple flows blood from an artery; from a thorn puncture in the left temple flows blood from a vein. All you have to know is a high school history lesson; that the circulation of blood in the body was unknown until it was described by Andrea Cesalpino in 1593; or, if your history text is in English, by William Harvey in 1628.

Dr. Rodante's original article, published in *Sindon* #24, October 1976, appeared in English translation in *Spectrum* by kind permission of the Author and with the blessings of Don Piero Coero-Borga. The present paper is an abridgment of that translation.

In this study we will objectively examine the bloodclots on the forehead, caused by the crown of thorns, as they appear in the black and white photo of the Holy Shroud; dark blood on the white background. It will be remembered that on the frontal imprint (Fig. 1), everything we see on our right corresponds to the right of the Crucified, and the direction of the blood flows toward the right (R) or toward the left (L) of the observer corresponds to the R or the L of the Crucified. The dorsal imprint (Fig. 2) is laterally reversed: the right of the image is at our left.

This being granted, we will study the puncture lesions caused on the head by the crown of thorns.

For many years I have observed the sindonic Face in the lifesize photo made by Giuseppe Enrie in 1931. I chose this particular photo in order to have the "real" vision and the precise dimensions of the bloodclots produced by a device that was meant to be an instrument of mockery but which, in effect, was one of torture.




Fig. 1: Frontal image, positive photo.

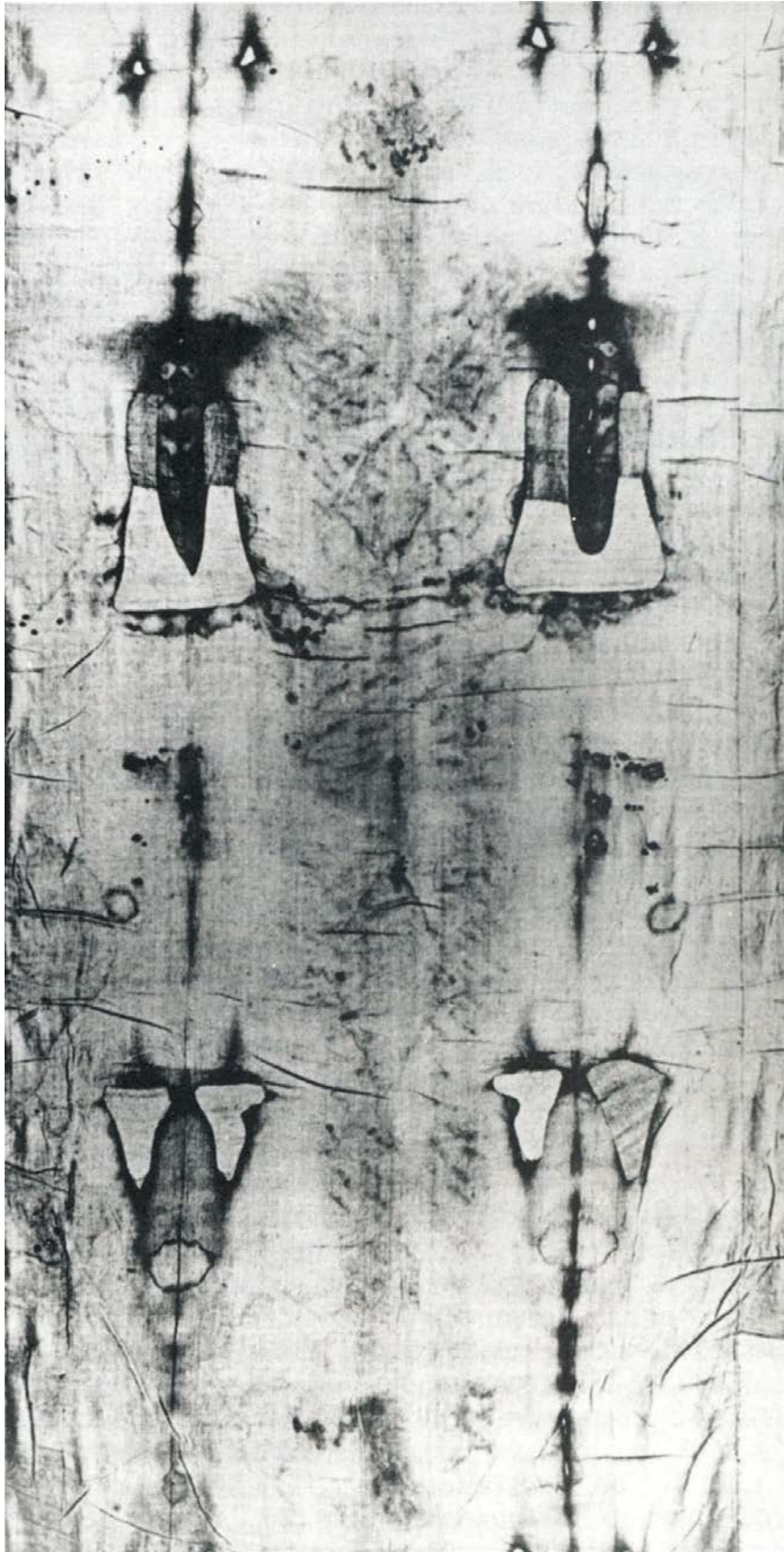


Fig. 2: Dorsal image, positive photo.

It is necessary to differentiate between puncture wounds caused by thorns implanted in a blood vessel of the head and afterwards removed; and wounds from thorns injuring a vessel and remaining in situ for a certain period of time. In the first case, there is the issue of blood, arterial or venous depending on the type of vessel injured, until the coagulative process at the point of the injury forms a clot, whereupon the bleeding toward the exterior ceases. In a healthy organism, in which the coagulative factors are normal, this process takes place in a few minutes.

Instead, the crown of thorns must have remained implanted on the head of the Crucified for a certain period of time, either before the crucifixion or during the hours in which he remained on the cross right up until death. In this case, each thorn remaining in situ partly blocked the issue of blood onto the skin, depending on the calibre of the perforated vessel. But the spasms of the forehead muscle, contracting because of the pain provoked by the injury-stimulus on the sensitive nerve endings, made the infixed thorns move, keeping the wounds open. If the injured vessel was a vein, there was a determination of blood in a slow and continuous flow, helped in its course by the movements of the wrinkling forehead. However, the perforation of an artery of a certain calibre, for example the frontal branch of the R superficial temple artery, by its own arterial pulsation caused movement at the point of perforation.

Therefore, while arterial pressure and the elasticity of the vessel walls, pulsing in systolic jets, aided the blood to issue around the implanted thorn, the thorn was moved externally by the pain contractions of the forehead muscle.

Across the forehead, we notice that there are clots isolated or in groups, and clots that, following the movement of the head and starting from the point of the wound on the skin, take a downward course in rivulets—perpendicularly or almost so—or diverge toward the R or toward the L (Fig. 3). The isolated clots, numbered 3, 5, 6, by their slimness show that they come from wounds in the cutaneous capillaries. Those in a group at numbers 8, 9, 10, 11, 12, 13, in the hair, —being of larger dimensions—issued from larger vessels situated between the bony sheath (theca), the muscular tissue and the skin. Finally, the clots running to R or to L, numbers 1, 4, 7, were produced by wounds in the walls of vessels of large enough calibre to allow the blood to issue in streams, running onto an area free of hair (forehead).

I counted these clots, relating each one to a wound, either superficial or deep. Logically, each venous perforation was determined by one thorn; but it cannot be excluded that some clots could have been the result of two perforating thorns, contiguous on the thorny wreath. So that on the forehead and in the frontal-temple area, R and L, there are at least thirteen perforations. In Figure 3 one notices three isolated drops: G1, which separates from the epsilon and terminates on the L eyebrow; G2, coming from flow #7, falls toward

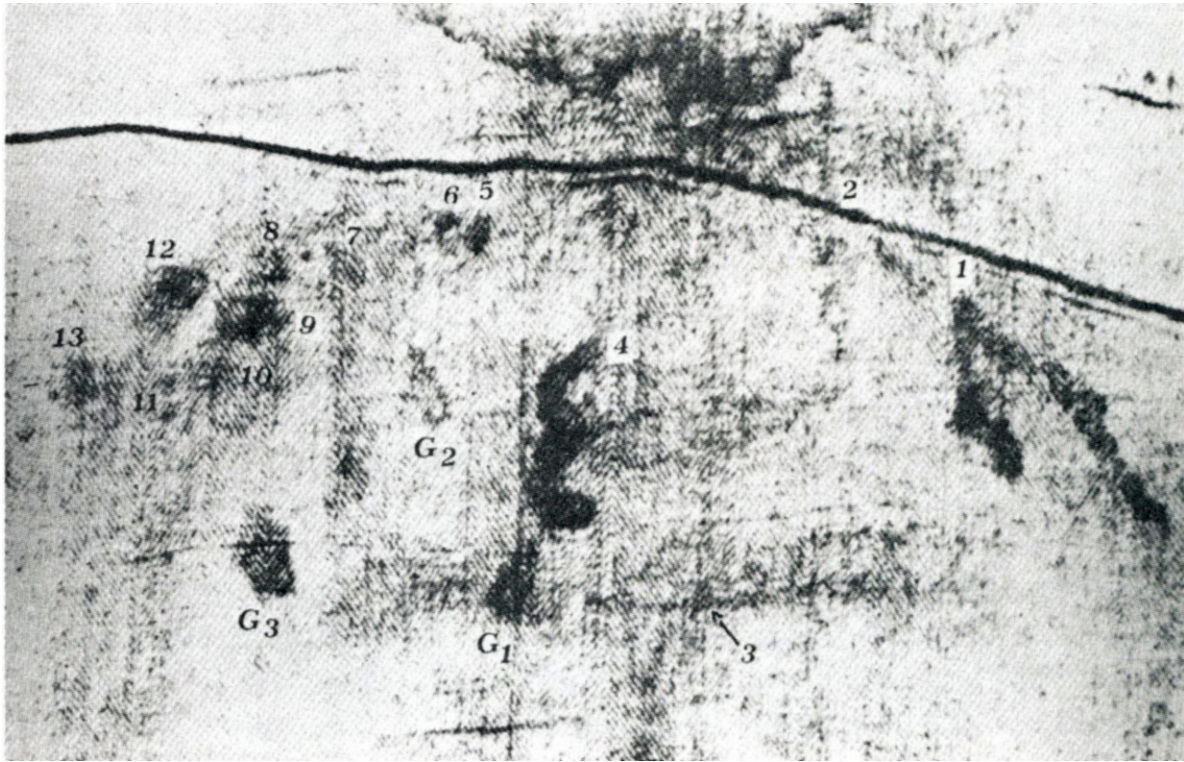


Fig. 3: Numbering of the forehead clots.

the R, forming a certain angle, indicating the movement of the head in that direction; G3, at the outside edge of the L eyebrow.

In contrast to the forehead clots, those of the back of the head cannot all be discerned: it is not possible to detect the rivulets hidden in the thick hair. Mons. Ricci has determined that: "Twelve bloodstreams with various directions start from eight wounds in the nape of the neck" (Fig. 4).

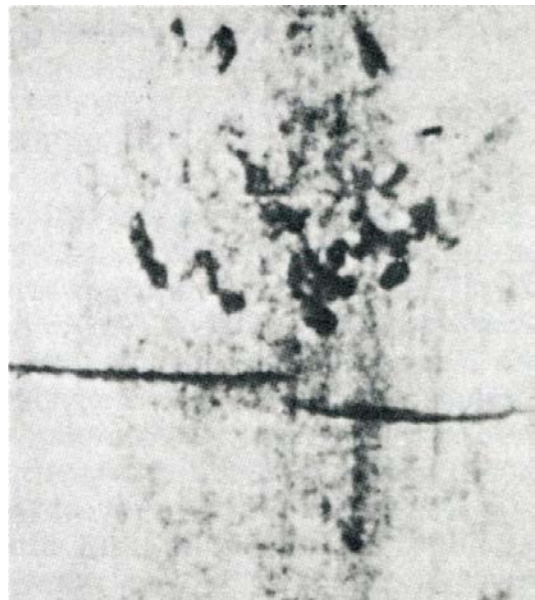


Fig. 4: Clots on the back of the head.

Completing the count of the clots, I have come to the conclusion that at least twenty thorns were implanted in the occipital region. And since the injuries reach the parietal-occipital area, we can suppose that the crown of thorns was in the form of a cap. These numerical calculations give us the

certainty that at least some thirty thorns—thirteen on the forehead, twenty in the occipital region—perforated the head in front and back. Since the sides of the head did not register, we have no way to study injuries produced in the parietal temple area, but we can deduce that some fifty or more thorns tortured the head of the Crucified.

In his study on the Passion and Death of Christ, La Cava writes: "After the scourging, Jesus was crowned with sharp thorns which, binding the head in a painful circle, was then beaten upon with canes.... To understand well the extent of this torture, it is enough to consider that the forehead, temples and, in general, all the scalp, are provided with a rich, sensitive nerve web derived in part from the trigeminal, in part from cervical nerves, whose nervous sensitivity are among the most painful in the human body. Think of the degree of painful sensations produced by dozens and dozens of extremely sharp, directly stimulating points, lacerating the nerve endings, not only of the skin, but also of all the layers of soft tissue of the scalp and even the cranial bones; and one will realize, with a certain approximation, the pain of the tragic coronation."

John the Evangelist tells us indirectly how the thorny material was right at hand, being used as fuel in those chilly nights of Jerusalem, 760-790 meters above sea level: "In the meantime, the servants and the guards, having made a bonfire of briars, because it was cold, stood around it to warm themselves" (On 18:18). Thus it was easy for the soldiers of the praetorium to obtain the spiny branches and improvise a tangle of sharp thorns to place, as a cruel joke, on the head of the Condemned.

After this look at the overall picture of the wounds produced by the crown of thorns, we will now study the individual bloodclots on the forehead. Much light on their formation and characteristics has been shed by notable authorities, especially Judica-Cordiglia, Caselli, Masera, Barbet, Hynek....

Caselli in particular, during the 1939 National Congress of Sindonic Studies, was the first to distinguish arterial blood from venous blood. "Analyzing these injuries, we see on the right temple (at the right of the observer, since the image is reversed as in a mirror) at the roots of the hair, a small puncture wound [Fig. 5, A1] from which two rivulets depart, one of which goes downward along the hair toward the shoulder, the other perpendicularly on the forehead toward the eyebrow. The thorn has injured the frontal branch of the superficial temple artery. The characteristic of the blood, in fact, is distinctly arterial."

To Caselli's truly important consideration, we add that the blood starting at the point of insertion of thorn A1 spurts out and arrives lower down, in a rivulet, along the frame of the hair, being impelled by the pulsation of this artery; the surge of blood in its course inside the vessel, having reached the point of the thorn's insertion, by the elasticity of the walls and by the arterial pressure, rhythmically opens the wound around the thorn, assisting the issue of blood. "Looking instead toward the middle of the forehead," Caselli continues, "a little to the left of the median line, we see a hemorrhage in the form of a reversed 3; blood that is dense, of homogeneous tint, uniform, opaque and very dark. It has distinct characteristics of venous blood, quite different from that of the right temple described

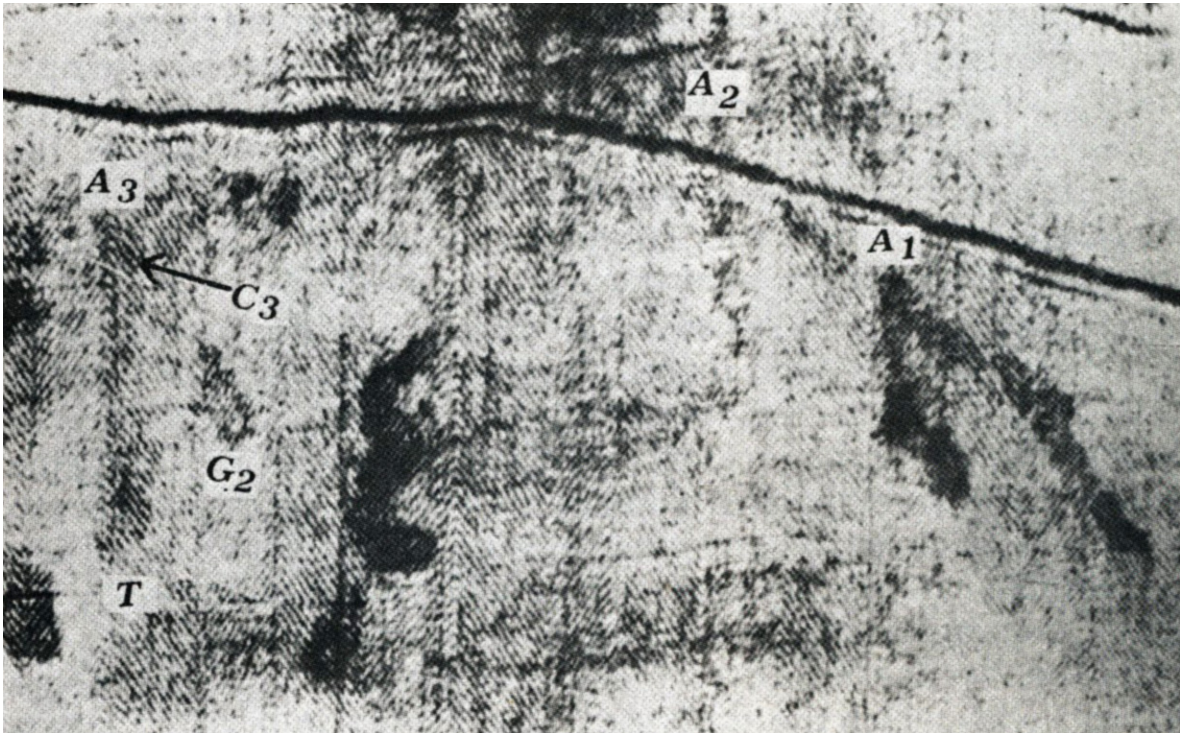


Fig. 5: In A3 can be seen the circular zone of the clot around thorn C3 and the venous blood which, falling slowly, becomes larger, forming the roundish terminal drop T.

above which, as we have seen, is arterial. Here the thorn certainly injured the forehead vein, called by anatomists the 'prepared vein'; sometimes single, more often double, as in this case.... The curious aspect of a 3 is due perhaps to the furrowing of the forehead muscle in spasms of pain."

After this surprising anatomical relationship, it seems to me closer to reality to differentiate the characteristics of venous blood, not so much by density or homogeneous uniformity, as put forth by Caselli's serious study, but more by the modality of the coagulation of venous blood ascribed to it so magisterially by Barbet. In analyzing the epsilon blood clot, Barbet says that it is blood with venous characteristics because it has "a slow and continuous downward flow. Several minutes are necessary for coagulation to take place. Only a small part, then, coagulates in the region of the wound. The farther down one goes on the image, the greater is the quantity of blood which has reached that level when it is time for it to coagulate. ...the successive sheets of blood accumulate their clots in successive layers. The total mass of clots is thus broader and thicker the lower one looks; and this is because the blood has met with obstacles."

Observing this clot (Fig. 6), we do indeed notice how, close to the wound, it is narrower and thinner, while farther from the puncture the clot is thicker and wider, as at the middle, or elbow, of the epsilon; and even more so farther down in the terminal area (knee of the epsilon) to the extent that a drop of blood (G1) falls onto the L eyebrow.

In various anatomy atlases, I have carefully observed the position of the frontal vein and the frontal branch of the superficial temple artery in respect to the location of the two clots studied above. The perfect correspondence of the forehead clots imprinted on the Cloth, reproducing the vein and the artery in mirror image, gives us the certainty that that linen covered the corpse of a man who, while living, suffered the lesion of these blood vessels.

I said "while living", because it is not possible to demonstrate by crowning a cadaver with thorns. A crown of thorns placed on the head of a corpse would cause not a drop of blood to issue forth from the scalp; or even if some came, even if one succeeded in injuring the frontal vein above the bifurcation or to perforate the frontal branch of the superficial temple artery, one could not produce a blood clot in the form of an epsilon, because the epsilon was determined by the spastic contractions of the forehead muscle as a reaction to the pain provoked by the lesion of the extremely fine, sensitive nerve endings with which the scalp is richly provided. A dead man does not react to pain. Nor could one obtain a clot of arterial blood at the temple which would fall far down along the hair, impelled by the pulsation of this "living" artery.

At this point I would like to make a logical consideration: We know that in the course of the centuries, the Shroud disappears from one place to reappear later somewhere else. Periods of absence more or less long which—we must be honest—certainly do not bolster the continuity of historical documentation concerning the passage of ownership of the Shroud. And historians rightly give weight to the serious lacunae.

But of the Shroud which has come down to us and which we are now studying, one thing is certain and cannot be placed in doubt by anyone: that this Shroud is the same one that, in 1534, the Poor Clare nuns of Chambéry, for fifteen days, mended with triangular linen patches over the triangular burns produced, two years earlier, during the fire in the sacristy of the Chambéry chapel.

Well, the fact that, for long periods in the peregrinations of the Shroud, there were serious historical gaps (begging the historians' pardon!) does not interest me. It does not even interest me to know what happened to the Shroud prior to 1534. I hold instead that it is of extreme importance to have the certainty that the Cloth which interests me is that of 1534.

Studying this Cloth, I limit myself to an objective examination only of the blood on the forehead, produced by a crown of thorns. And I come to the conclusion, as I said above, that "the perfect correspondence of the forehead bloodclots imprinted on the Sheet in mirror image at the vein and the artery being studied, gives us the certainty that that Sheet covered the corpse of a man who, while alive, endured the lesion of these blood vessels". So—since the circulation of blood, that is, the difference between arterial blood and venous blood, was discovered by Andrea Cesalpino in

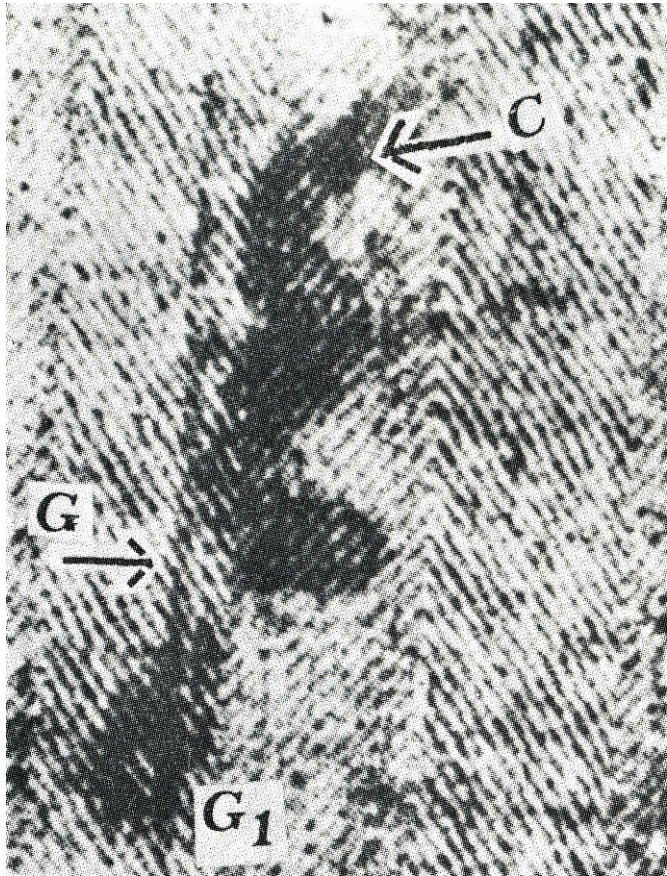


Fig. 6: C indicates the circular clot around the infixed thorn. G: the knee of the epsilon lacks its natural roundness. G1: drop of blood fallen or "torn" from the knee.



Fig. 7 Clot on the wrist.

1593-61 years after the fire—nobody anterior to the fire could possibly have had a precise notion of the different modalities of coagulation, on the skin, of arterial blood and venous blood.

This, for me, a medical doctor who seeks to study the bloodstains objectively, is the most important intrinsic detail that constrains me to testify, in incontrovertible manner, over and above any existing historical gaps, to the authenticity of the Shroud, a medico-legal document.

Regarding the forehead clots, Mons. Ricci had the merit to establish the movements of the head of the Crucified during the whole torture. He followed the observation first made by Barbet who attentively studied the flow on the L wrist, which on the cross had to flow perpendicular to the ground, according to the laws of gravity. Barbet wrote: "This flow divides into two diverging traces, forming an angle of about 10 degrees (Fig. 7). To escape asphyxia on the cross, the Crucified must have assumed two positions; of slumping forward and straightening up." Measuring more exactly the angle of the two diverging rivulets of the wrist, Ricci determined the movements of the head, deduced from the angles of some rivulets on the forehead (Fig. 5). In fact, the blood flows A1, A2, A3, each starting from the points of penetration of a thorn, take two directions denoting movements of the head caused by the two positions; the straightening up caused the head to bend to the right, but when

the body hung in the state of slump the head fell forward and immobile at the center. The two positions of the head resulted in the vertical flow and the flow toward the right of the blood from the three wounds remaining open on the forehead when Jesus hung on the cross.

In my opinion, it should be specified that flow A3, diverging to the R in the L temple region, is not formed by a rivulet but by the droplet G2, which fell from the point of perforation above it at one of the times when the head leaned toward the R, its axis thereby marking the angle of opening in relation to the inclination of the head. Concerning what Mons. Ricci established, we can therefore be certain that the three rivulets were produced by the crown of thorns that the Condemned was wearing while he was on the cross. The three thorns, remaining infixed in the three vessels, and at the same time being moved inside their elastic walls by the forehead muscle that contracted with pain, contributed to the issue of the bloodstreams with angles diverging to the R, first studied by Ricci.

Returning to the origin of these trickles; from the studies of Caselli, cited above, we know that the trickle of the R temple region derives from the forehead branch of the superficial temple artery (Fig. 5, flow A1). I have observed at length and for a long time the other two flows, A2 and A3. Having had the Enrie photo printed in natural size in black and white and with a bit more contrast, I was able to better study the characteristics of coagulation.

Flow A2 is disturbed by a dark wrinkle in the Sheet. Since the imprint of the two rivulets, one perpendicular, the other diverging to the R, is somewhat pale on the Cloth, despite the greater contrast achieved in this photo one cannot establish, from the manner of efflux and coagulation, whether it was an artery or a vein that was lesioned.

But one can study quite well the flow A3, which, with the drop G2, forms the angle diverging to the R. At the origin of the skin injury, one notices a roundish formation C3, dark enough to denote a more homogeneous color around the thorn. The trickle descends perpendicularly downward, slowly and continuously, helped, so to speak, by the movement of the thorn in the vessel walls as a result of contractions of the forehead muscle. This rivulet, formed in the slumping position, gradually thickens as it flows down from the wound, so that in the terminal part T, it forms a large roundish drop. The mass of the clot, therefore, is that much thicker and wider the farther it is from the wound. Such behavior then, as also for the epsilon clot, denotes venous blood.

I have closely observed the position of clot A3 and its opposite A1, which is arterial. Dividing the Face into two parts (Fig. 8) with a line passing along the ridge of the nose, on the natural size photo it is seen that the puncture in the superficial temple artery A1, is at 3.6 cm from the outside edge of the R eyebrow and 5.3 cm from the median line. Observing now the position of clot A3, one sees that

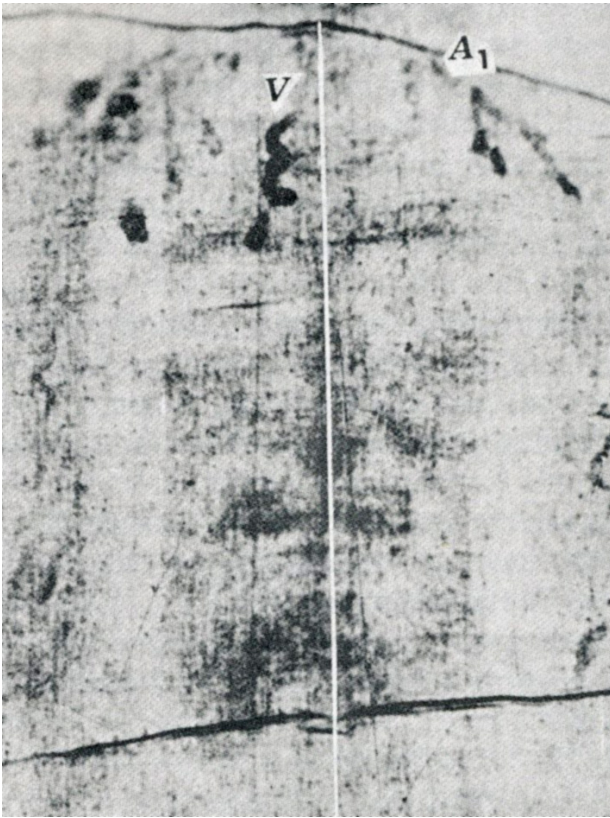

Fig. 8: Position of the frontal vein V and the frontal branch of the superficial temple artery A1. The venous clot V lies to the left of the median line.

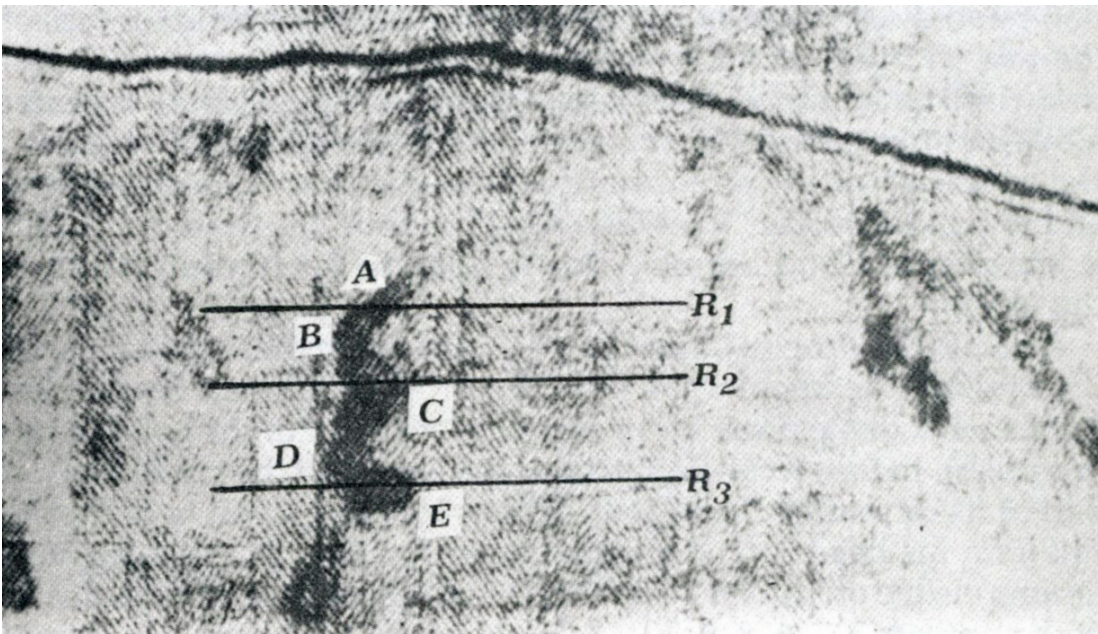


Fig. 9: Movements of the head toward the left (AB and CD) and toward the right (BC and DE).

the skin lesion around the infixed thorn is at 4.3 cm from the outside edge of the L eyebrow and at 4.8 cm from the median line. This clot, with venous characteristics, is therefore 7 mm higher and 5 mm more inward than its opposite A1, which comes from the frontal branch of the superficial temple artery.

A last look at the forehead, to focus on the venous clot in form of an epsilon (Fig. 9). Here one sees quite well the circular clot C

around the thorn which perforates the frontal vein. Since the rivulet has assumed this form not only by the furrowing of the forehead muscle (pain reaction), but especially by the movements of the head to R and to L, one can be certain that it would have been formed before the crucifixion. In fact, the line AB and CD denote a movement of the head toward the L; the line BC a movement toward the R; and even the terminal line DE flows from L to R, along a forehead furrow.

Using a tube of narrow calibre, I let some citrated blood run for about 5 minutes onto the forehead of a colleague who, keeping his head immobile, wrinkled and relaxed his forehead muscle. The blood fell slowly and perpendicularly, surmounting the obstacles of the moving wrinkles but without forming any elbow or knee.

The epsilon form, then, was not produced solely by the wrinkling of the forehead but especially by movements of the head to R and to L. Thus we have reason to think that this clot was formed in the atrium of the praetorium during the coronation mockery, i.e., before the crucifixion. We read in Mt 27:29, 30: "And braiding a crown of thorns, they put it on his head ... took a cane and beat on the head". And in Mk 15: 17-19: "And braiding a crown of thorns they put it on him ... and beat on his head with a cane".

The cane-blows on the head were evidently dealt in every direction by soldiers who took turns at hitting the king's head for fun; on the top, in front, at right, at left, on the nape of the neck. Only a thorn infixed in the forehead vein, a thorn moving with the repeated blows and the painful furrowing of the forehead, could produce a clot so abundant and so accurate. And as the blows brandished to R and to L induced the "Crowned King" to bend his head to L and to R, the venous blood, running slowly from the open wound, formed the epsilon.

A detail: the drop of blood G1 (Fig. 6) fell from the terminal part of the epsilon (the knee) upon the L eyebrow as if it had been jerked from such a distal place by an abrupt movement of the head (a slap or a push). In fact, it can be seen that the knee G of the epsilon lacks a part of its rotundity. "And the soldiers, braiding a crown of thorns, put it on his head ... and slapped him" (Jn 19:2, 3). Also the other lesions visible on the forehead which, in Figure 3 we have indicated with numbers 3, 5, 6, 8, 9, 10, 11, 12, 13, could have been determined by blows on the spiny wreath. Numbers 3, 5, and 6 show evidence of small clots, the small capillary vessels having been injured; while numbers 8, 9, 10, 11, 12 and 13 are larger clots coming from wounds in arteries and veins of a certain calibre. Where the blood issued onto the hair, it could not give the characteristic flows which, on the free zone of the forehead, permitted us to differentiate arterial blood from venous blood.

In the atrium of the Antonia fortress, the soldiers, finding themselves for the first time in their careers before a malefactor who dared to proclaim himself a king, impatient to give vent to their glee,

must surely have improvised a crown by twining the bramble branches hurriedly and at random. The observation springs spontaneously that the blows of the cane must have injured also the blood vessels on the sides of the head; but since on the Shroud the sides are not printed, it is not possible to take them into consideration.

The clots of the nape (Fig. 4) do fall under our observation; some were formed as a result of the blows in the praetorium, but most of all by the repeated falls on the way to Calvary. Observing the L knee on the frontal imprint of the Shroud, one notices an excoriation surely due to falls on a stony terrain. One may be permitted, then, to think that during the staggering and the falls, the patibulum struck against the occipital region, driving in the thorns more deeply.

The blood clots of the nape have been studied quite well by Judica-Cordiglia and Caselli. But this present paper has been limited to considerations of the coagulation differences, on the skin, between arterial blood and venous blood. And this is only possible on the forehead, free of hair. Every observer can see the evidence on the Face and forehead of the Man of the Shroud.

We have now reached the end of this study. We have striven to present an objective examination of the clots, differentiating, wherever possible, between the arterial and the venous characteristics solely by their modality of coagulation on the skin. This distinction, together with the number and position of the wounds and direction of the flows, has brought us, indirectly, to relieve the Man's torment. May we submit ourselves, in love, to such atrocious outrage.

REFERENCES

PIERRE BARBET: *La Passione di Cristo secondo il chirurgo*, Lice, Padua, 1965; *Le cinque piaghe di Cristo*, S.E.I., Turin, 1940

GIUSEPPE CASELLI: "Le constatazioni della medicina moderna sulle impronte della S. Sindone", *La S. Sindone nelle ricerche moderne*, Lice, Turin, 1950

GIOVANNI JUDICA-CORDIGLIA: *La Sindone*, Lice, Padua, 1961

FRANCESCO LA CAVA: *La Passione e la morte di N. S. Gesù Cristo illustrata dalla scienza medica*, D'Auria, Naples, 1953

GIULIO RICCI: *L'Uomo della Sindone patì sotto Ponzio Pilato?*, Porziuncola, Assisi, 1960; *L'Uomo della Sindone è Gesù*, Studium, Rome, 1969